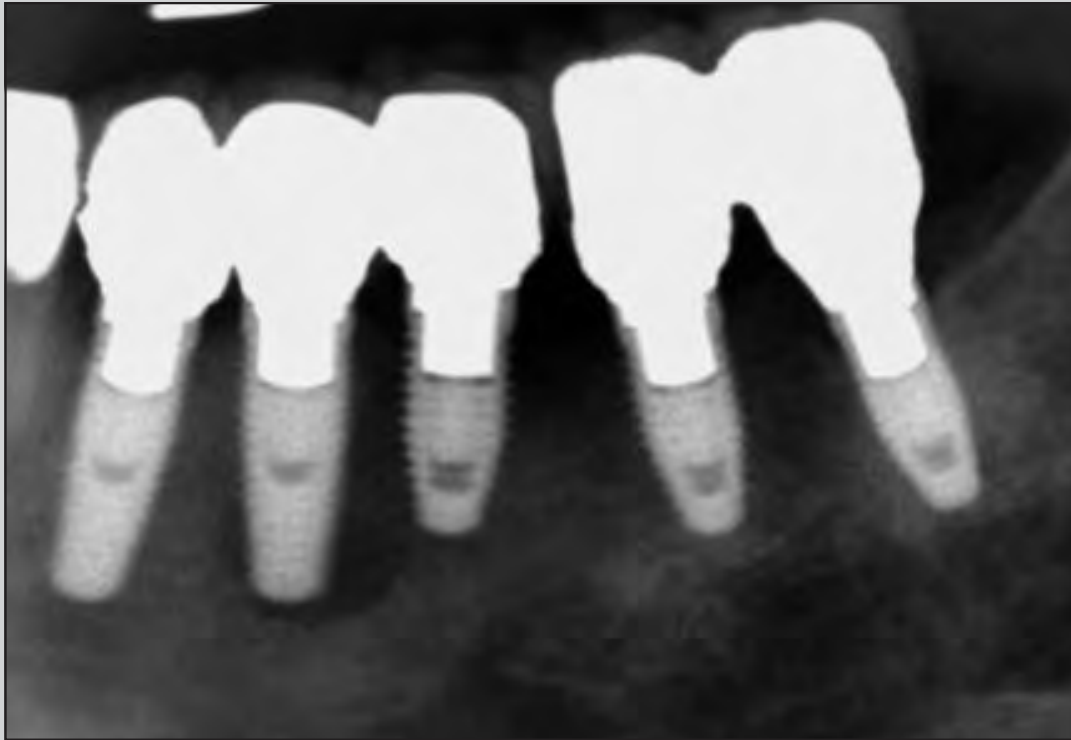
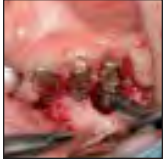
Treatment of Peri-implantitis Around TiUnite-Surface Implants Using Er:YAG Laser Microexplosions



Atsuhiko Yamamoto, DDS, PhD¹
Toshiichiro Tanabe, DDS, PhD²

Implant therapy can lead to peri-implantitis, and none of the methods used to treat this inflammatory response have been predictably effective. It is nearly impossible to treat infected surfaces such as TiUnite (a titanium oxide layer) that promote osteoinduction, but finding an effective way to do so is essential. Experiments were conducted to determine the optimum irradiation power for stripping away the contaminated titanium oxide layer with Er:YAG laser irradiation, the degree of implant heating as a result of Er:YAG laser irradiation, and whether osseointegration was possible after Er:YAG laser microexplosions were used to strip a layer from the surface of implants placed in beagle dogs. The Er:YAG laser was effective at removing an even layer of titanium oxide, and the use of water spray limited heating of the irradiated implant, thus protecting the surrounding bone tissue from heat damage. Peri-implantitis can be effectively treated using Er:YAG laser irradiation. (Int J Periodontics Restorative Dent 2013;33:21–29. doi: 10.11607/prd.1593)

¹Lecturer, The Japan Institute for Advanced Dental Studies (JIADS), Osaka and Tokyo, Japan; President, Perio-Implant Hospital AUTIS, Osaka, Japan.

²Associate Professor, Department of Implantology, Division of Oral Pathogenesis and Disease, Asahi University School of Dentistry, Gifu, Japan.

Correspondence to: Dr Atsuhiko Yamamoto, 5-4-16 Fujisawadai, Tondabayashi, Osaka, Japan; fax: +81 721-29-4182; email: autis@silver.ocn.ne.jp.

©2013 by Quintessence Publishing Co Inc.

Although osseointegrated dental implants have been documented to have high survival rates, the surrounding tissues may be subject to inflammatory conditions similar to periodontal disease. There are two types of inflammatory conditions: peri-implant mucositis and peri-implantitis. Peri-implant mucositis is defined as the presence of inflammation in the soft tissue surrounding a dental implant without any loss of supporting bone. Peri-implantitis involves both soft tissue inflammation and loss of implant bony support. Associated with risk factors such as inadequate oral hygiene, a history of periodontitis, and cigarette smoking,¹ peri-implantitis has been reported to occur in 28% to 56% of subjects.² While many methods of treating peri-implantitis have been proposed, none have been established as overwhelmingly superior.^{3–8} Various lasers have been used to treat peri-implantitis but only to sterilize the surface of the implant, not to remove the contaminated matter.⁹

One promising treatment protocol is decontamination of the surface of a failing implant with an Er:YAG laser.^{10–16} Until recently, the

Er:YAG laser has been used to treat peri-implantitis without opening a flap. Inflammation has been treated by irradiating the pocket around the implant. However, this only aims to treat the inflammation, not address the underlying cause of the inflammation.¹⁷ Therefore, no consensus exists regarding the optimal methodology for using Er:YAG lasers to treat peri-implantitis.

This study aimed to (1) determine the optimal irradiation power for stripping away a layer of the TiUnite (titanium oxide) implant surface using Er:YAG laser irradiation, (2) determine the degree of implant heating resulting from Er:YAG laser irradiation, and (3) determine whether osseointegration was possible in an animal model after stripping the surface of the contaminated titanium oxide layer with Er:YAG laser microexplosions.

Method and materials

Optimal irradiation power

To determine the optimal irradiation conditions to steam-strip a titanium oxide surface layer using an Er:YAG laser (Erwin AdvErl, J. Morita), 15 3.75 × 13-mm Brånemark MkIII RP TiUnite implants (Nobel Biocare) were irradiated using the PS600T tip (J. Morita) on the Er:YAG laser; the flat quartz tip tapers from 600 μm in the upper portion to 400 μm in the lower portion. An electric X-Y stage was used (ALD-904-H1, Chuo Precision Industrial) and set at a speed of 0.2 mm/s. The distance from the end of the

tip to the implant surface was set at 0.05 mm. Surface ablation was set to 50 mJ/mm², 100 mJ/mm², and 200 mJ/mm² by monitoring the energy at the top of the tip with a power meter rather than relying on the display value indicated by the laser since the light-guiding fiber and the tip attenuate the laser power. A new tip was used for each implant, and the laser power was measured every time. The pulse was set to 20 PPS, water was injected at a rate of 5 mL/min, and the irradiation time was 15 seconds. Changes at the irradiated surfaces were examined using an optical microscope and a phase contrast electron microscope.

Implant heating


The neck of a 3.75 × 13-mm Brånemark MkIII RP TiUnite implant was fixed in an acrylic resin plate to simulate clinical conditions. Using an Er:YAG laser (Erwin AdvErl) with a PS600T tip, the implant head was irradiated at tip-end output powers of 100 mJ (10 PPS) and 50 mJ (20 PPS) for 15 seconds (total, 1,500 mJ of energy). Irradiation was performed both with and without water spray at a rate of 5 mL/min.

The implant was irradiated under four conditions: (1) with water spray at 100 mJ and 10 PPS, (2) without water spray at 100 mJ and 10 PPS, (3) with water spray at 50 mJ and 20 PPS, and (4) without water spray at 50 mJ and 20 PPS. The increase in temperature was monitored using a thermograph (Neo Thermo TVS-700, Nippon Avionics).


Five implants were heated for each condition, and the next set of conditions was tested using the same implants after they had cooled to room temperature, as monitored by the thermograph. Temperature increase was monitored with a thermograph instead of a thermocouple since measuring the surface temperature should reflect the temperature of the portion in contact with bone cells and because preliminary experiments show that the temperature cannot be accurately measured with a thermocouple since Er:YAG irradiation causes temperature increases in the thermocouple as well. In order to compare the level of implant heating when using different types of lasers, a separate experiment was carried out using a carbon dioxide (CO₂) laser (Laserwin, J. Morita). The CO₂ laser unit was not equipped with a spray, so the authors performed a separate test using it with and without a separate spray device. The difference in heating was approximately 10°C. Therefore, it was decided to use the CO₂ laser unit without spray and as it was originally intended with a flow of cooling air at a rate of 260 mL/min.

Osseointegration of newly laser-irradiated implants

All molars were extracted from both sides of the mandible in six 18-month-old female beagle dogs, each weighing approximately 12.0 kg. After 3 months, radiographs were taken to confirm that the extraction cavities had healed



Figs 1a to 1c (a and b) Phase contrast electron micrographs. The TiUnite layer has been completely stripped away by microexplosions. The newly exposed surface has not melted or been deformed by the heating effect of laser irradiation. The left and top portions show the surface before Er:YAG laser irradiation, while the right and bottom portions show the surface after laser irradiation. (c) Implant with laser treatment on the apical portion.



properly. An Er:YAG laser was used to irradiate and strip one-half of the surface of 24 3.75 × 13-mm TiUnite implants. Two implants were placed in each extraction site, with an initial torque of 35 to 45 Ncm. The implants were placed so that the irradiated half was on the buccal aspect and the nonirradiated half was on the lingual aspect. Two animals were sacrificed after 2 weeks, two more were sacrificed after 4 weeks, and the final two were sacrificed after 6 weeks. Tissue samples were dyed with hematoxylin-eosin without decalcification to prepare the observation samples. Images with magnifications of 10× and 200×

were captured at 2, 4, and 6 weeks. For consistency, images at 200× magnification were taken between the fourth and fifth threads.

Results

Optimal irradiation power

At 50 mJ/mm², the TiUnite layer could not be entirely removed. At 100 mJ/mm², an even layer of the TiUnite surface was effectively removed, and the newly exposed surface did not appear to be deformed by melting, carbonization, or other effects of heating (Fig 1).

At 200 mJ/mm², the TiUnite layer as well as the titanium layer underneath had melted.

Implant heating

The results are shown in Fig 2. When the implant was irradiated with the Er:YAG laser using the water spray for cooling, the temperature of the implant increased by a maximum of 3°C for both output conditions (100 mJ at 10 PPS and 50 mJ at 20 PPS). However, when used without water spray, the temperature of the implant head increased by 30°C and 33°C at 100 mJ and

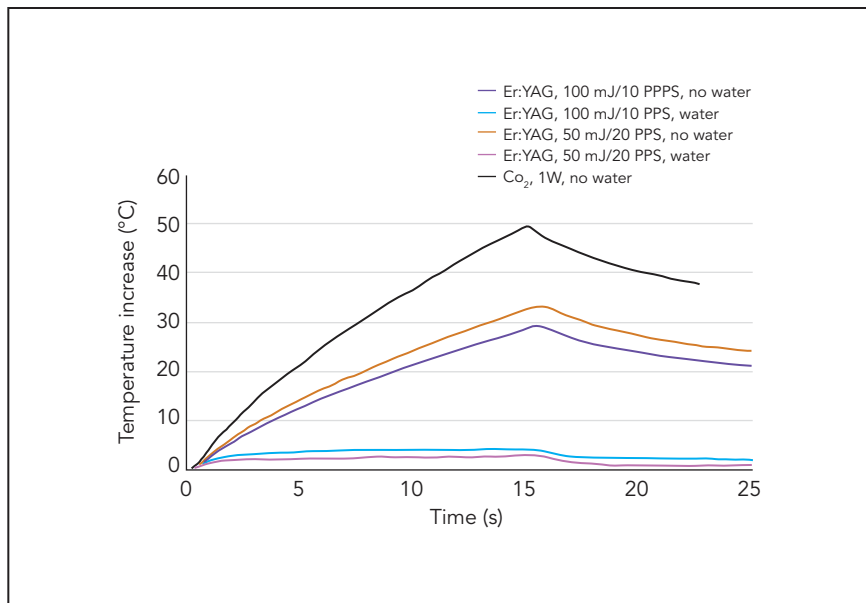


Fig 2 Temperature increases with laser irradiation. The results dictate that the Er:YAG laser be used with water spray to treat peri-implantitis.

10 PPS and at 50 mJ and 20 PPS, respectively. The CO₂ laser raised the temperature of the implant head by 50°C, even with the cooling air set for maximum flow.

Osseointegration of newly laser-irradiated implants

Figures 3a to 3c show an implant after 2 weeks at 10× and 200× magnifications. Slight incursion of bonelike tissue was noted on both the nonirradiated (Fig 3b) and irradiated surfaces (Fig 3c). Figures 4a to 4c show an implant after 4 weeks at 10× and 200× magnifications. Bonelike tissue was still being formed on the nonirradiated surface (Fig 4b), and bonelike tissue was also forming along the surface of the irradiated surface and

filled in approximately one-third of the gap (Fig 4c). Figures 5a to 5c show an implant after 6 weeks at 10× and 200× magnifications. Bone formation can be observed on both the nonirradiated (Fig 5b) and irradiated surfaces (Fig 5c).

Discussion

Optimal irradiation power

If the structure in question has a cavelike structure similar to TiUnite, a laser could hypothetically be used to remove the bacteria and impurities embedded in it. However, it is difficult for lasers, the beams of which travel in a straight line, to penetrate deep into such irregular structures. Therefore, the authors believe that it is desirable

for the TiUnite surface layer (the contaminated titanium oxide layer) to be stripped away. The Er:YAG laser has by far the greatest degree of absorption with water—almost 10× more than CO₂ lasers, almost 70,000× more than Nd:YAG lasers, and almost 600,000× more than diode lasers. When the Er:YAG laser energy is absorbed by water, the water immediately turns into steam. The volume of the water expands by 1,000×, resulting in microexplosions. The authors believe this effect might be useful for peri-implantitis treatment.

These findings suggest that while using a power setting of less than 100 mJ/mm² might effectively disinfect the surface, the TiUnite layer will be completely stripped away by the Er:YAG laser microexplosions.

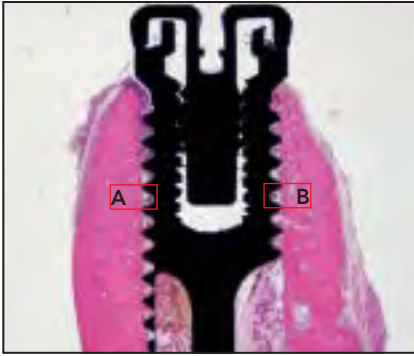


Fig 3a Histologic sample 2 weeks after implantation.

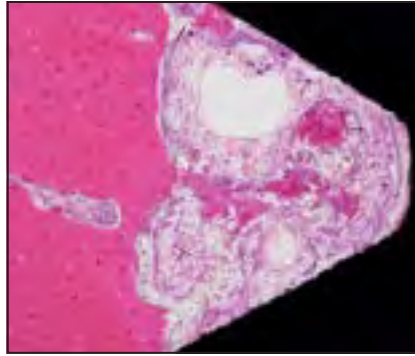


Fig 3b Nonirradiated TiUnite surface with the original, nonablated TiUnite surface layer (magnified view of highlighted area A in Fig 3a; original magnification $\times 200$).

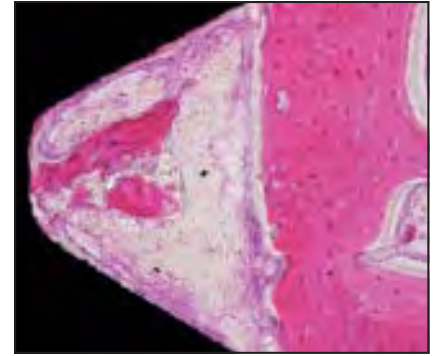


Fig 3c Er:YAG laser-stripped surface (magnified view of highlighted area B in Fig 3a; original magnification $\times 200$).

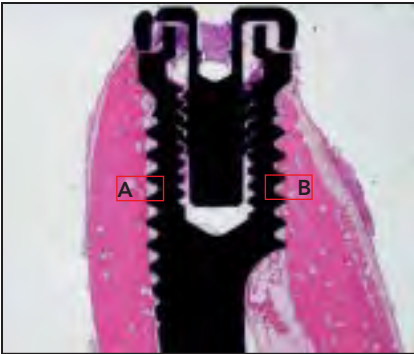


Fig 4a Histologic sample 4 weeks after implantation.

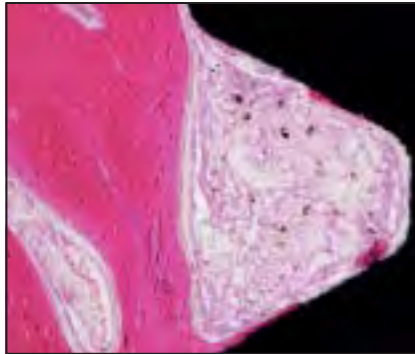


Fig 4b Nonirradiated TiUnite surface (magnified view of highlighted area A in Fig 4a; original magnification $\times 200$).

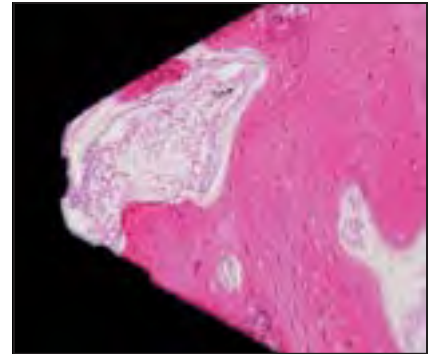
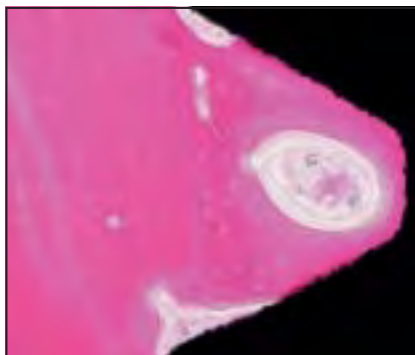


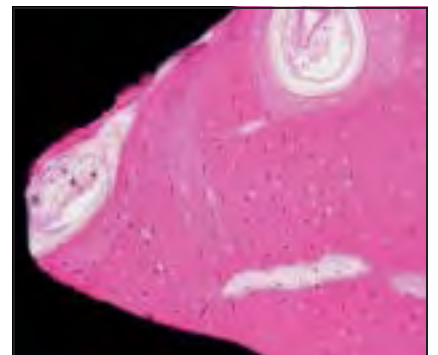
Fig 4c The Er:YAG laser-stripped surface clearly shows the growth of new bone cells (magnified view of highlighted area B in Fig 4a; original magnification $\times 200$).

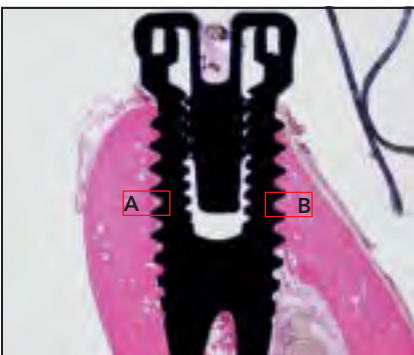

Fig 5a Histologic sample 6 weeks after implantation.



Figs 5b and 5c Bone growth can be observed on both (b) nonirradiated (magnified view of highlighted area A in Fig 5a) and (c) Er:YAG laser-irradiated surfaces (magnified view of highlighted area B in Fig 5a). Thus, osseointegration is possible for the Er:YAG laser-stripped surface (original magnification $\times 200$).



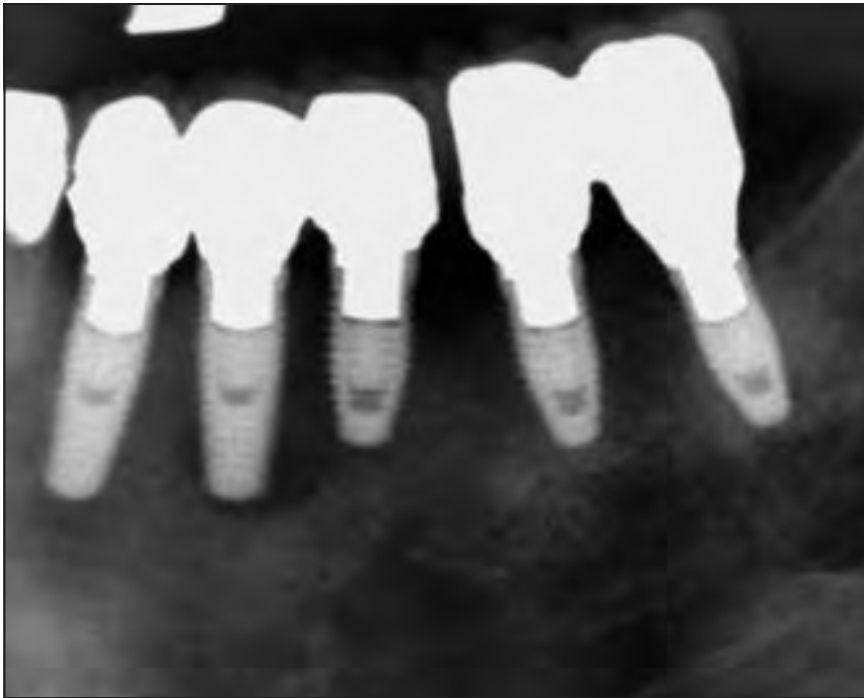


Fig 6 Radiograph showing considerable bone loss around the implants in the mandibular left posterior quadrant.

Implant heating

Boulnois¹⁸ found that individual cells begin to deform and die between 43°C and 45°C and that proteins degenerate and coagulate at 60°C. Although the CO₂ laser has been reported to be only slightly absorbed by titanium and to cause no changes in surface morphology, the present results indicate that irradiation of a titanium implant by a CO₂ laser may heat it sufficiently to cause bone tissue necrosis.

Use of an Er:YAG laser without water spray could cause similar damage. However, when an Er:YAG

laser is used with water spray, heating is minimized and no irreversible damage is caused.

Osseointegration of newly laser-irradiated implants

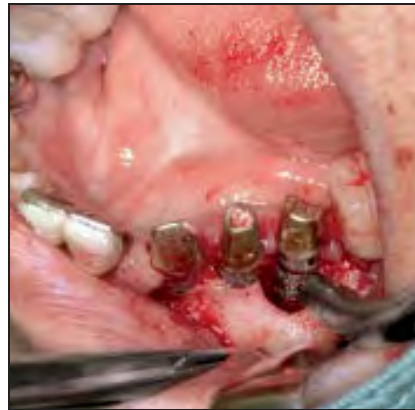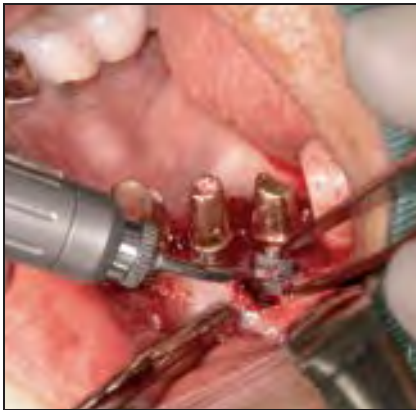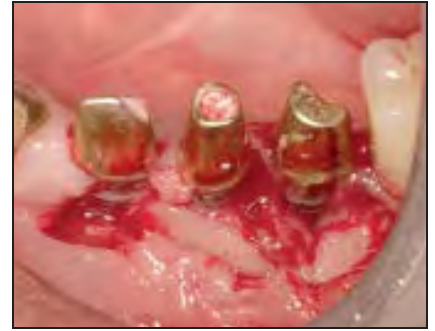The animal experiments showed that osseointegration occurred on the fresh, uncontaminated surface produced by laser irradiation. Further, Kreisler et al¹⁰ reported that the implant surface is sterilized by Er:YAG laser irradiation. These results strongly suggest that the difficulties of treating peri-implantitis

can be overcome with Er:YAG laser irradiation because it is possible to strip away the contaminated titanium oxide layer and create a fresh, disinfected implant surface without damaging the implant threads. This new surface appears to have osteoinductive properties that are as effective as the original (non-laser irradiated) TiUnite surface.

Clinical case

The following clinical case illustrates the use of an Er:YAG laser to treat a patient with peri-implantitis.

Fig 7 After raising a buccal flap, a large amount of inflamed granulation tissue was removed using the Er:YAG laser.



Figs 8a and 8b The key to removing contaminated granulation tissue with an Er:YAG laser is to irradiate not the granulation tissue itself but the layer where the granulation tissue and healthy bone tissue meet. In this way, the contaminated granulation tissue can be removed in a single mass. After removing the granulation tissue, the contaminated TiUnite surface layer was stripped away and sterilized.

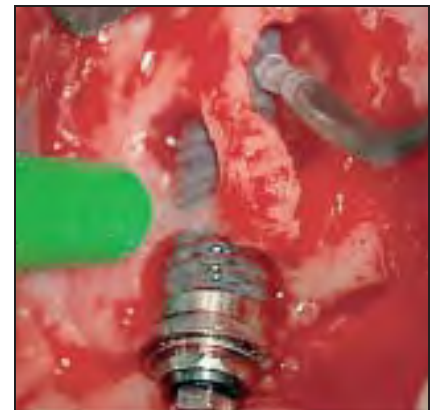

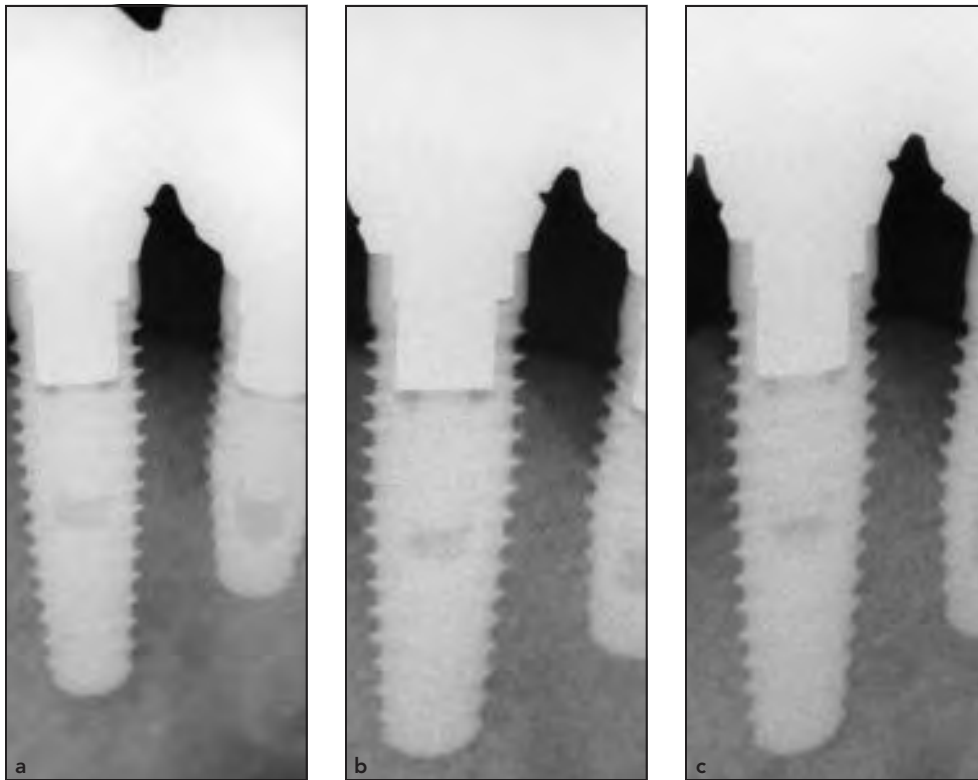
Fig 9 Using the Er:YAG laser with water spray keeps the implant from overheating. The microexplosions created when the laser strikes the water remove blood and other visual obstructions.

In September 2006, an 81-year-old woman received a total of nine implants, five of which are shown in Fig 6: the mandibular left canine site, first and second premolar, and first and second molar. After 4 months, provisional restorations were placed, and 6 months later, the definitive restorations were delivered. After 1 year, the patient complained of swelling around her implants. Radiographic examination showed considerable resorption around the implants in the region of the mandibular left posterior quadrant (Fig 6). The superstructure was removed, and it was

discovered that the implants were not loose. However, the inflammation extended to the bone—a clear case of advanced peri-implantitis. Further examination determined that this was a CIST (cumulative interceptive supportive therapy) Class D case (probing depth > 5 mm, positive for bleeding on probing, and bone loss > 2 mm). The peri-implantitis was treated using Er:YAG laser irradiation.

After the patient had received a local anesthetic (2% xylocaine), a buccal flap was reflected at the mandibular left quadrant. Although the implants were not loose, consid-

erable bone resorption and granulation tissue were found (Fig 7). The infected granulation tissue was ablated and removed by laser irradiation using a PS600T tip at 50 mJ power and 20 PPS with a 5-mL/min sterilized water spray (Figs 8a and 8b). Granulation tissue is normally removed using a curette, but the resultant bleeding prevents a clear view of the treatment area. The Er:YAG laser with water spray eliminates this problem. The application of water spray and the microexplosions caused by the laser light hitting the water maintain visibility in the treatment area (Fig 9).



Figs 10a to 10c Radiographs taken (a) 3 months and (b) 2 and (c) 3 years after treatment showing stabilized bone growth.

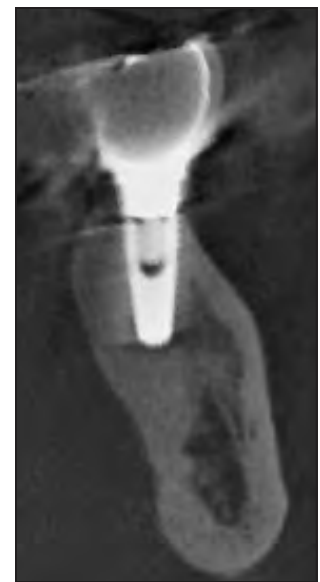

Fig 11 Computed tomography scan 4 years after treatment. The peri-implantitis had been resolved, and the area around the implant had stabilized.

After removing the infected granulation tissue, the contaminated implant surface was sterilized by ablating a layer of the TiUnite surface. A PS600T tip was lightly guided over the surface at 50 mJ power and 20 PPS with a 5-mL/min water spray. The contaminated layer was stripped away by the microexplosions caused by the Er:YAG laser reaction with the water spray. Slightly dark gray areas could be seen on the ablated surface, which were not a result of carbonization but rather the new titanium surface

showing through. Implants are usually placed vertically, and when the laser is applied perpendicular to the implant, it can easily reach detailed features of the threads and thoroughly sterilize the contaminated titanium oxide layer by stripping away an even layer.

An autogenous bone graft was placed and covered with a resorbable membrane, and the site was closed in the conventional manner. Radiographs were taken 3 months and 2 and 3 years after surgery (Figs 10a to 10c), all of which

showed apparent bone regeneration. A computed tomography scan (buccolingual cross section) was obtained 4 years after treatment (Fig 11). The area around the implant had stabilized.

Conclusions

The microexplosions produced by an Er:YAG laser can effectively remove the contaminated titanium oxide layer from an implant that is failing because of peri-implantitis.

When accompanied by water spray, irradiation with the Er:YAG laser limits heating of the implant to a few degrees, which is not enough to damage the surrounding bone tissue and inhibit osseointegration. The animal experiments reported also showed that osseointegration is possible on the fresh surface produced by laser irradiation.

Acknowledgments

The authors would like to thank Drs Yoshihiro Ono, Yasukazu Miyamoto, Toshiaki Yoshino, and Akira Aoki for their continuing support. The authors reported no conflicts of interest related to this study.

References

1. van Winkelhoff AJ. Consensus on peri-implant infections [in Dutch]. *Ned Tijdschr Tandheelkd* 2010;117:519–523.
2. Zitzmann NU, Berglundh T. Definition and prevalence of peri-implant diseases. *J Clin Periodontol* 2008;35(suppl): 286–291.
3. Schou S, Berglundh T, Lang NP. Surgical treatment of peri-implantitis. *Int J Oral Maxillofac Implants* 2004;19:140–149.
4. Claffey N, Clarke E, Polyzois I, Renvert S. Surgical treatment of peri-implantitis. *J Clin Periodontol* 2008;35(suppl):316–332.
5. Ungvári K, Pelsöczy IK, Kormos B, et al. Effects on titanium implant surfaces of chemical agents used for the treatment of peri-implantitis. *J Biomed Mater Res B Appl Biomater* 2010;94:222–229.
6. Persson GR, Samuelsson E, Lindahl C, Renvert S. Mechanical non-surgical treatment of peri-implantitis: A single-blinded randomized longitudinal clinical study. II Microbiological results. *J Clin Periodontol* 2010;37:563–573.
7. Schwarz F, Sahn N, Iglhaut G, Becker J. Impact of the method of surface debridement and decontamination on the clinical outcome following combined surgical therapy of peri-implantitis: A randomized controlled clinical study. *J Clin Periodontol* 2011;38:276–284.
8. Persson LG, Ericsson I, Berglundh T, Lindhe J. Osseointegration following treatment of peri-implantitis and replacement of implant components. An experimental study in the dog. *J Clin Periodontol* 2001;28:258–263.
9. Deppe H, Horch HH, Henke J, Donath K. Peri-implant care of ailing implants with the carbon dioxide laser. *Int J Oral Maxillofac Implants* 2001;16:659–667.
10. Kreisler M, Kohnen W, Marinello C, et al. Bactericidal effect of the Er:YAG laser on dental implant surfaces: An in vitro study. *J Periodontol* 2002;73:1292–1298.
11. Renvert S, Lindahl C, Roos Jansåker AM, Persson GR. Treatment of peri-implantitis using an Er:YAG laser or an air-abrasive device: A randomized clinical trial. *J Clin Periodontol* 2011;38:65–73.
12. Stubinger S, Etter C, Miskiewicz M, et al. Surface alterations of polished and sandblasted and acid-etched titanium implants after Er:YAG, carbon dioxide, and diode laser irradiation. *Int J Oral Maxillofac Implants* 2010;25:104–111.
13. Badran Z, Bories C, Struillou X, Saffarza-deh A, Verner C, Soueidan A. Er:YAG laser in the clinical management of severe peri-implantitis: A case report. *J Oral Implantol* 2011;37(spec no):212–217.
14. Takasaki AA, Aoki A, Mizutani K, Kiuchi S, Oda S, Ishikawa I. Er:YAG laser therapy for peri-implant infection: A histological study. *Lasers Med Sci* 2007;22:143–157.
15. Schwarz F, Sculean A, Rothamel D, Schwenzer K, Georg T, Becker J. Clinical evaluation of an Er:YAG laser for nonsurgical treatment of peri-implantitis: A pilot study. *Clin Oral Implants Res* 2005;16: 44–52.
16. Schwarz F, Bieling K, Sculean A, Herten M, Becker J. Treatment of periimplantitis with laser or ultrasound. A review of the literature [in German]. *Schweiz Monatsschr Zahnmed* 2004;114:1228–1235.
17. Schwarz F, Bieling K, Bonsmann M, Latz T, Becker J. Nonsurgical treatment of moderate and advanced periimplantitis lesions: A controlled clinical study. *Clin Oral Investig* 2006;10:279–288.
18. Boulnois JL. Photophysical processes in recent medical laser development. *Lasers Med Sci* 1986;1:47–66.